

CORRECTION

Open Access



# Correction to: Laparoscopic repair of an incarcerated diaphragmatic hernia after right hepatectomy for hepatic injury: a case report

Shohei Takaichi<sup>1</sup>, Tsuyoshi Takahashi<sup>1\*</sup>, Soichiro Funaki<sup>2</sup>, Koji Tanaka<sup>1</sup>, Yasuhiro Miyazaki<sup>1</sup>, Tomoki Makino<sup>1</sup>, Yukinori Kurokawa<sup>1</sup>, Makoto Yamasaki<sup>1</sup>, Kiyokazu Nakajima<sup>1</sup>, Meinoshin Okumura<sup>3</sup>, Masaki Mori<sup>1</sup> and Yuichiro Doki<sup>1</sup>

## Correction to: Surg Case Rep

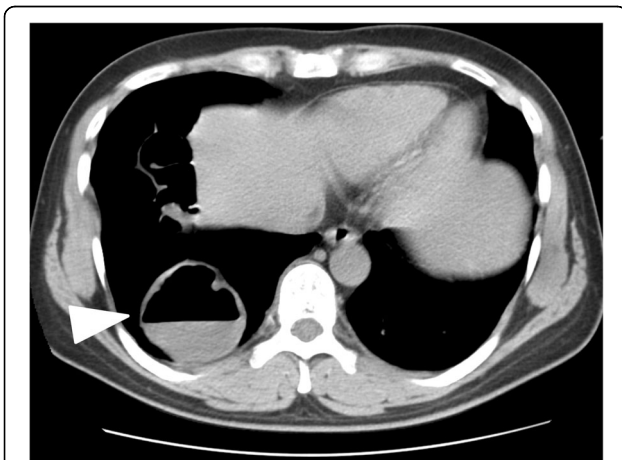
<https://doi.org/10.1186/s40792-018-0542-0>

In the original publication of this article [1], the author found Fig. 1c has a redundant arrow. The correct Fig. 1c is below:

Received: 30 November 2018 Accepted: 3 December 2018  
Published online: 21 December 2018

## Reference

1. Takaichi, et al. Laparoscopic repair of an incarcerated diaphragmatic hernia after right hepatectomy for hepatic injury: a case report. *Surg Case Rep.* 2018;4:135 <https://doi.org/10.1186/s40792-018-0542-0>.



**Fig. 1 c** Computed tomography showing the herniated transverse colon located in the right thoracic cavity (arrow head)

## Author details

<sup>1</sup>Department of Gastroenterological Surgery, Osaka University Graduate School of Medicine, 2-2 Yamadaoka, Suita, Osaka 565-0871, Japan.

<sup>2</sup>Department of respiratory Surgery, Osaka University Graduate School of Medicine, Osaka, Japan. <sup>3</sup>Toneyama National Hospital, 5-1-1 Toneyama, Toyonaka, Osaka 560-8552, Japan.

\* Correspondence: [ttakahashi2@gesurg.med.osaka-u.ac.jp](mailto:ttakahashi2@gesurg.med.osaka-u.ac.jp)

The original article can be found online at <https://doi.org/10.1186/s40792-018-0542-0>

<sup>1</sup>Department of Gastroenterological Surgery, Osaka University Graduate School of Medicine, 2-2 Yamadaoka, Suita, Osaka 565-0871, Japan